

Immune Reconstitution Inflammatory Syndrome: A Reappraisal

Martyn A. French

Department of Clinical Immunology and Immunogenetics, Royal Perth Hospital, and PathWest Laboratory Medicine School of Pathology and Laboratory Medicine, University of Western Australia, Perth, Australia

Individuals with human immunodeficiency virus infection who commence antiretroviral therapy when they are very immunodeficient are susceptible to immune reconstitution disorders. The most common disorders are the various forms of immune restoration disease (IRD) that appear to result from the restoration of a dysregulated immune response against pathogen-specific antigens. Essentially, any pathogen that can cause an opportunistic infection as a result of cellular immunodeficiency can provoke IRD when pathogen-specific immune responses recover during antiretroviral therapy. In resource-poor countries, *Mycobacterium tuberculosis* and *Cryptococcus neoformans* are the most significant pathogens, because the former causes substantial morbidity and the latter causes substantial mortality. IRD associated with these pathogens is characterized by severe inflammatory responses and is often referred to as immune reconstitution inflammatory syndrome. Prevention and treatment strategies for IRD are being developed, but preliminary data have demonstrated the efficacy of corticosteroid therapy in severe cases. Immune reconstitution after antiretroviral therapy may also be associated with autoimmune disease or sarcoidosis, both of which appear to have an immunopathogenesis that is different from that of IRD.

Contemporary antiretroviral therapy (ART) is both potent and tolerable for long periods. Consequently, a majority of individuals with HIV infection who achieve optimal adherence to ART will experience at least partial reversal of HIV-induced immune defects and reconstitution of the immune system (table 1). It remains unclear whether complete immune reconstitution ever occurs, but it is clear that patients who commence ART when they are very immunodeficient are susceptible to immune reconstitution disorders [1]. A group of these disorders is characterized by inflammatory and/or autoimmune disease and is commonly referred to as immune reconstitution inflammatory syndrome (IRIS) [2]. It has become apparent that IRIS consists of several distinct disorders that appear to result from dysfunction of those aspects of immune reconstitution that affect restoration of pathogen-specific immune responses and/or immune regulation. Although it is acknowl-

edged that there are still uncertainties about the immunopathogenesis of IRIS, sufficient information has been obtained from clinicopathological and immunological studies to permit a discussion of the etiology of the different components. Therefore, in this review, the components of IRIS will be considered separately as immune restoration disease (IRD), which is a consequence of the restoration of an immune response against pathogen-specific antigens that results in immunopathology, and immune reconstitution-associated autoimmune disease and sarcoidosis; these are also adverse outcomes of immune reconstitution but are not directly related to the restoration of pathogen-specific immune responses.

With respect to IRD in patients with HIV infection, this review will particularly focus on 3 aspects. First, it will focus on the immunopathogenesis of IRD in patients with HIV infection, because studies of the immunopathogenesis have the potential to not only improve diagnostic methods and treatment but also provide novel insights into the characteristics of pathogen-specific immune responses and their regulation. This information might also be applicable to other situations in which immune reconstitution disorders occur, such as in patients who have undergone haematopoietic stem cell transplantation and/or in those who receive intensive immunosup-

Received 27 May 2008; accepted 29 August 2008; electronically published 24 November 2008.

Reprints or correspondence: Dr. Martyn French, Dept. of Clinical Immunology, Royal Perth Hospital, GPO Box X2213, Perth, WA 6847, Australia (martyn.french@health.wa.gov.au).

Clinical Infectious Diseases 2009;48:101-7

© 2008 by the Infectious Diseases Society of America. All rights reserved.

1058-4838/2009/4801-0016\$15.00

DOI: 10.1086/595006

Table 1. Immune reconstitution in patients with HIV infection.

Characteristic
Replenishment of immune cells depleted directly or indirectly (via immune activation) by HIV infection
Circulating immune cells
Immune cells in other compartments of the immune system (e.g., mucosal)
Regeneration of primary and secondary lymphoid organs, particularly those damaged by HIV-induced inflammation
Thymus
Lymph nodes
Gut-associated lymphoid tissue
Restoration of pathogen-specific T, B, and NK cell responses
Recovery of memory T and B cell responses
Repertoire diversity of T and B cell antigen receptors
Response to new antigens
Regulation of the reconstituted immune system

pressant therapy. Second, the review will focus on IRD of the CNS, and third, IRD in resource-poor countries will be discussed; both topics pose major problems in clinical practice.

IRD

The most important aspect of immune reconstitution is the restoration of immune responses against pathogen-specific antigens. When this occurs in patients who are infected with a pathogen, the desired outcome is eradication—or at least control—of the infection. However, in some patients, the restored immune response causes immunopathology while eradicating the infection. The inflammation that arises may be misinterpreted as an opportunistic infection, but it results from the restoration, rather than from the loss, of a pathogen-specific immune response and is therefore IRD rather than immunodeficiency disease [1, 3, 4]. As shown in table 2, an assessment of the clinicopathological and immunological characteristics of infectious disease in patients receiving ART can differentiate IRD from immunodeficiency disease. Although IRD usually results in inflammation of tissues infected with the pathogen, cellular proliferative disease may also occur, as exemplified by cases of Kaposi sarcoma that becomes worse or present for the first time after ART is commenced [6].

Essentially, any pathogen that can cause an opportunistic infection as a result of impaired cellular immune responses can provoke IRD after pathogen-specific immune responses are restored by ART. ART-associated hepatotoxicity or hepatitis flares in patients coinfecting with hepatitis B virus or hepatitis C virus may also be the result of IRD in the liver, although there is debate about this in hepatitis C virus infection [7]. It also appears that HIV infection itself can provoke IRD [8].

Infections that provoke IRD may be subclinical before the initiation of ART and may be unmasked by the immune re-

sponse. This type of IRD usually presents during the first 3 months of therapy, and viable pathogens may be isolated from samples obtained from affected body sites, particularly when there is tissue necrosis. Initiation of ART in a patient who has recently had an opportunistic infection that has been treated may also result in IRD, which may appear to be a paradoxical relapse of the infection. This form of IRD is also most common during the first 3 months of therapy but may present later. In patients with such cases, the immune response appears to be against the antigens of nonviable pathogens; therefore, pathogens may not be cultured from biopsy or fluid samples obtained from affected body sites. Paradoxical IRD associated with treated *Mycobacterium tuberculosis* or cryptococcal infection is a particularly notable problem that occurs in 8%–43% of patients with treated tuberculosis [9–12] and 4%–66% of patients with treated cryptococcal infection [13–16]. Paradoxical IRD is also exemplified by immune recovery uveitis, which occurs in eyes previously affected by cytomegalovirus retinitis [17]. This condition commonly presents months to years after the commencement of ART.

Immunopathogenesis of IRD. The immunopathology of IRD is largely determined by the provoking pathogen. Examination of the histopathologic characteristics and/or inflammatory cell infiltrate of affected tissues or organs has demonstrated that CD8⁺ T cells predominate in IRD that is provoked by viruses, such as JC virus [18], HIV [8, 18], and cytomegalovirus [19]. In contrast, granulomatous inflammation usually predominates in IRD that is provoked by fungi, such as *Histoplasma* species and cryptococci [14, 20]; by protozoans, such as *Leishmania* species [21]; and by mycobacteria, such as *M. tuberculosis*, *Mycobacterium leprae* [22, 23], and nontuberculous mycobacteria [5]. In patients with *M. tuberculosis* or cryptococcal IRD, the inflammation is often associated with other characteristics of a Th1 immune response, including increased numbers of circulating T cells that produce IFN- γ when they are stimulated with pathogen-specific antigens [24–26]. Mycobacterial IRD may also present with suppuration of lymph nodes or other affected organs [5, 12, 27, 28]. The immunopathology in such cases is unclear at present, but tissue suppuration might reflect a Th17 response against mycobacterial antigens [29], because Th17 responses induce inflammation that is often mediated by neutrophils [30]. The immunopathology of IRD that presents as cellular proliferative disease is presumably different and might reflect the production of cytokines that induce cellular proliferation, as suggested by preliminary data from serological testing of samples from patients who developed Kaposi sarcoma after initiating ART [31]. Serological testing has also been of value in other situations, such as for patients with HIV and hepatitis B virus coinfection who experienced hepatitis flares after commencement of ART; increased plasma levels of immune mediators suggest that the

Table 2. Differing characteristics of immune restoration disease and immunodeficiency disease in patients with HIV infection.

Variable	Immune restoration disease	Immunodeficiency disease
Cause	Immunopathology resulting from the restoration of a “protective” pathogen-specific cellular immune response	Result of failure of “protective” cellular immune responses to control pathogen replication
HIV RNA level	Always associated with a decrease in the plasma HIV RNA level	Usually associated with a high plasma HIV RNA level ^a
CD4 ⁺ T cell count	Usually associated with an increased circulating CD4 ⁺ T cell count ^b	Associated with a low circulating CD4 ⁺ T cell count
Inflammation	Inflammation is atypical in presentation and/or more exaggerated than in immunodeficiency disease (e.g., pain, suppuration, and necrosis)	Inflammatory responses may be blunted
Testing	Examination of affected tissue or body fluid samples reveals evidence of an immune response (e.g., scarcity of pathogens, infiltrating lymphocytes, and granulomatous inflammation) ^c	Examination of affected tissue or body fluid samples reveals evidence of an impaired immune response (e.g., abundance of pathogens and poorly formed granulomata in mycobacterial disease)
Pathogen-specific immune response	Pathogen-specific cellular immune responses are increased ^d	“Protective” pathogen-specific immune responses are impaired
Treatment	The infection may resolve without treatment	Antimicrobial therapy is required to resolve the infection

^a Patients with long-term control of HIV replication may rarely have persistent immune defects that are complicated by opportunistic infections.

^b The circulating CD4⁺ T cell count is not increased in some patients with immune restoration disease (e.g., ~10% of patients with *Mycobacterium avium* complex immune restoration disease do not have an increased CD4⁺ T cell count) [5].

^c Viable pathogens may be isolated from tissue, exudate, or body fluid samples in “unmasking” immune restoration disease.

^d This has been demonstrated directly for only a small number of pathogens but has been demonstrated indirectly by clinicopathological and serological studies for many others.

flares reflect IRD in the liver [32]. Examination of intraocular fluid specimens has demonstrated that increased IL-12 production is a component of the immunopathology in immune recovery uveitis [17].

Considered together, the aforementioned findings suggest that IRD is the result of an immune response that is “protective” in character but excessive by degree, probably because it is inadequately regulated. The cause of the putative defect of immune regulation is unclear and is likely to affect several immune cell populations (figure 1). Preliminary data indicate that patients with *M. tuberculosis* or cryptococcal IRD do not have fewer circulating regulatory T cells (CD4⁺, CD25^{hi}, CD127^{lo}, and FoxP3⁺ T cells) than do patients who do not develop IRD [26]. Indeed, the proportion of circulating CD4⁺ T cells with a regulatory T cell immunophenotype is increased in patients with severe HIV-induced immunodeficiency in association with immune activation [33]. A defect of induced regulatory pathways mediated by adaptive and/or innate immune cells remains a possibility.

Many studies have consistently shown that the major risk factor for the development of IRD is a CD4⁺ T cell count <100 cells/ μ L [3, 34]. In patients who develop paradoxical IRD, a disseminated infection with the provoking pathogen and/or a short duration between treatment of the infection and com-

mencement of ART are also risk factors [9, 11–14]. All of these risk factors may be markers of a high pathogen load resulting in a large amount of antigen against which an immune response is generated. A very low CD4⁺ T cell count may also signify a high probability of immune activation and/or immune dysregulation before and during the restoration of pathogen-specific immune responses.

IRD of the CNS. IRD of the CNS deserves special consideration, because the morbidity and mortality associated with IRD of the CNS are much greater than the morbidity and mortality associated with other types of IRD. An inflammatory form of progressive multifocal leucoencephalopathy of the brain appears to represent IRD associated with JC virus infection [35, 36]. It presents after the commencement of ART as either an exacerbation of established progressive multifocal leucoencephalopathy (i.e., “paradoxical” IRD) or as a first presentation of progressive multifocal leucoencephalopathy (i.e., “unmasking” IRD). The latter is associated with substantial morbidity and mortality; rates of up to 50% have been reported [36]. MRI of the brain often demonstrates more inflammation than would be expected for progressive multifocal leucoencephalopathy complicating AIDS, and examination of a brain biopsy specimen usually reveals an inflammatory cell infiltrate with a predominance of CD8⁺ T cells [18, 35]. There have also

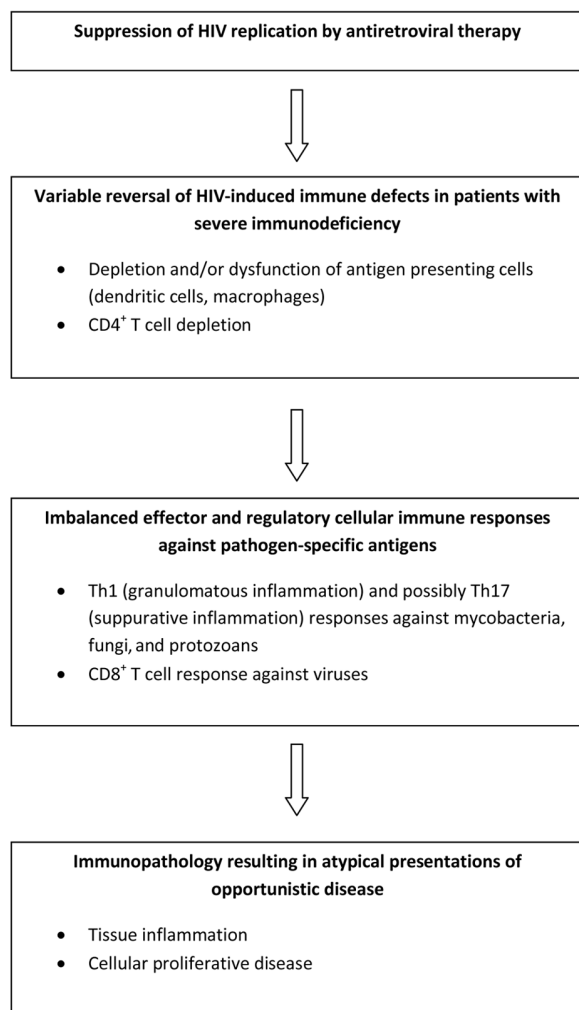


Figure 1. Postulated disease mechanisms in immune reconstitution disease

been a small number of reports of HIV encephalitis worsening after commencement of ART [8, 18]. This has also been associated with a CD8⁺ T cell infiltrate in the brain, which might reflect an increase in circulating HIV-specific CD8⁺ T cells during the early course of ART [37]. Many other pathogens have been associated with IRD of the brain, including *M. tuberculosis*, *Cryptococcus* species, *Toxoplasma gondii*, herpes simplex virus, varicella zoster virus, and parvovirus B19 [38]. Permanent neurological disability is not uncommon. Myelitis after commencement of ART may result from IRD in the spinal cord [38], which can be investigated by analysis of lymphocytes in the CSF by flow cytometry [39].

Meningitis resulting from “unmasking” IRD associated with cryptococcal or *M. tuberculosis* infection may present during the first few weeks of ART. When IRD is associated with cryptococcal infection, cryptococci can be cultured from CSF samples, and preliminary data indicate that the number of circu-

lating *Cryptococcus* species-specific T cells is increased [26]. A more common presentation is with what appears to be a relapse of previously treated meningitis during the course of effective ART. When such a relapse is associated with cryptococcal infection, it is characterized by a high CSF opening pressure and is associated with a high fatality rate [13–16]. Evidence that this is IRD rather than immunodeficiency disease (table 2) includes failure, in most cases, to culture cryptococci from the CSF samples, although cryptococcal antigen is usually present. Although meningitis resulting from “paradoxical” cryptococcal IRD may present during the first 3 months of ART, cases often present later (up to 3 years after the commencement of ART) [14]. Meningitis is presumably the result of an immune response against cryptococcal antigens retained in the meninges—similar to the immune response that results in mediastinal lymphadenitis in some patients with cryptococcal IRD [40]. An exacerbation of meningitis in a patient receiving effective ART may pose a diagnostic dilemma, because it is unclear whether it represents a recurrence of the infection because of persistent immunodeficiency or represents IRD resulting from an immune response against retained cryptococcal antigens. The distinction is important, because corticosteroid therapy might be considered to treat IRD but might exacerbate an active cryptococcal infection resulting from persistent immunodeficiency.

Involvement of the CNS by IRD poses many challenges in diagnosis and management; however, it also presents opportunities to understand the immunopathogenesis and to improve diagnostic methods, because markers of the immunopathology can be examined in CSF samples. Possible markers include activated lymphocyte populations [39] and intrathecal production of antibodies to pathogens that might be provoking IRD, such as JC virus [41]. Diagnostic tests that assess cryptococcus-specific immune responses in blood and/or CSF samples should also be evaluated in patients with cryptococcal IRD.

IRD in HIV-infected patients from resource-poor regions of the world. As predicted [4], IRD has become a significant complication of ART in HIV-infected patients from resource-poor countries [42], particularly in those patients who are also infected with *M. tuberculosis*. IRD associated with previously treated *M. tuberculosis* infection is commonly known as tuberculosis IRIS and has a variety of clinical presentations, including pneumonitis, lymphadenitis, ileitis, hepatitis, suppurating masses, and serous effusions [11, 12, 42–45]. Use of health care resources to manage tuberculosis IRIS is a substantial problem, but mortality is uncommon, with death occurring in ~1% of patients [11, 44]. Diagnosis is often problematic, especially in the most resource-poor regions of the world [28]. Tuberculosis presenting after the commencement of ART is also a significant problem in HIV-infected patients from resource-poor countries; the incidence among these pa-

tients is ~20 times higher than that among HIV-infected patients from resource-rich countries [28, 45]. Tuberculosis presenting after ART initiation also appears to be a form of IRD, but the immunopathogenesis may be different from that of tuberculosis IRIS [25].

Prospective studies of IRD in a South African population demonstrated that cryptococcal IRD is a less common complication of ART than is *M. tuberculosis* IRD [44]. However, mortality is much more common among patients with cryptococcal IRD than among patients with *M. tuberculosis* IRD, with rates of 40%–66% being reported from South Africa and Uganda [15, 16]. Mortality associated with IRD might, therefore, contribute to the higher rates of early death and loss to follow-up after the commencement of ART that occurred among patients from resource-poor countries, compared with those from resource-rich countries [46].

Prevention and management of IRD. The incidence of paradoxical IRD associated with *M. tuberculosis*, *Cryptococcus* species, and cytomegalovirus infection is higher among patients who have received less treatment for the infection than among those who have received more treatment [9, 11–14, 47]. This presumably reflects a larger amount of antigen that initiates the immune response. Therefore, it could be argued that delaying the commencement of ART in patients who are receiving therapy for an opportunistic infection will reduce the risk of IRD. However, the risks of developing IRD must be balanced against the risks of worsening of HIV disease if ART is deferred. Furthermore, the risks and benefits of delaying ART should not be generalized and need to be examined in randomized clinical trials for each pathogen.

The evidence base for producing guidelines on the treatment of IRD is very limited and relies heavily on clinical observations and expert opinion [48]. Anti-inflammatory therapy may be effective but should be reserved for the most severe cases; this is especially true of corticosteroid therapy, which can increase the risk of reactivating other latent infections. ART should only be ceased if disease is life threatening. In cases of paradoxical IRD, treatment of the opportunistic infection should be continued to suppress replication of the provoking pathogen and to reduce antigen load.

IMMUNE RECONSTITUTION–ASSOCIATED AUTOIMMUNE DISEASE

Various autoimmune diseases have been reported in patients with HIV infection that responds to ART. For the large majority of these reports, it remains unclear whether the association with ART-induced immune reconstitution is just a coincidence. However, Graves disease presenting after the initiation of ART has been reported in >40 HIV-infected patients [49–51], which provides compelling evidence that at least this particular autoimmune disease is a complication of ART-induced immune

reconstitution. The median CD4⁺ T cell count before the commencement of ART in patients presenting with Graves disease during ART-induced immune reconstitution was 10 cells/ μ L (range, 0–305 cells/ μ L), indicating that previous severe immunodeficiency is a major risk factor. In contrast with IRD, Graves disease was associated with a median time to presentation of ~21 months after the commencement of ART.

Graves disease and other autoimmune diseases are also associated with immune reconstitution after the use of alemtuzumab therapy in patients who do not have HIV disease [52–55]. Alemtuzumab is a monoclonal antibody to CD52 that induces extensive depletion of T and B cells. Therefore, Graves disease that occurs after immune reconstitution appears to affect individuals who have recovered from severe T cell depletion. The immunopathogenesis of Graves disease after recovery from severe T cell depletion has not been defined but might result from an acquired defect of immune tolerance that results in an increased susceptibility to autoimmune disease [56]. There is preliminary evidence of a defect of central T cell tolerance resulting from thymus dysfunction in some HIV-infected patients [57]. Defects of peripheral T cell tolerance have not been investigated but might include impaired function of the T cell immunoregulatory receptor cytotoxic T lymphocyte antigen 4 (CTLA-4). This molecule appears to have an important role in the maintenance of T cell tolerance to thyroid autoantigens [58, 59]. Patients with HIV infection who had a nadir CD4⁺ T cell count <50 cells/ μ L and who experienced a substantial increase in their CD4⁺ T cell count while receiving ART have increased proportions of circulating CD4⁺ T cells producing CTLA-4 [60]. This might result in higher levels of circulating soluble CTLA-4, which impairs the interaction of CTLA-4 with its ligands CD80 or CD86 on antigen-presenting cells [59]. Additional investigation of the role of CTLA-4 in immune reconstitution-associated autoimmune disease is required.

IMMUNE RECONSTITUTION–ASSOCIATED SARCOIDOSIS

Sarcoidosis is another potential complication of immune reconstitution in patients who have received ART for HIV infection [61, 62] and for patients who have received alemtuzumab therapy [63] and/or undergone haematopoietic stem cell transplantation [64]. Other immune-mediated inflammatory disease (including photodermatitis [65]) in HIV-infected patients receiving ART might also be a complication of immune reconstitution.

Sarcoidosis in patients with HIV infection who are receiving ART may present up to 3 years after the commencement of ART. Clinicopathological characteristics of sarcoidosis in HIV-infected patients are similar to those of sarcoidosis in HIV-uninfected patients. Sarcoidosis has been reported to occur after

use of IL-2 or IFN- α therapy in both HIV-infected patients [62] and HIV-uninfected persons [66]. Therefore, it appears that immune reconstitution after T cell depletion resulting from a number of causes, including HIV infection, is associated with an increased susceptibility to immune dysregulation that induces the Th1 immune responses against unknown antigens that underlie the granulomatous inflammation of sarcoidosis [67]. The susceptibility to dysregulated Th1 immune responses is presumably increased further by the use of IFN- α or IL-2 therapy, both of which enhance Th1 responses.

In HIV-infected patients receiving ART, it is important to differentiate immune reconstitution-associated sarcoidosis from IRD that results in granulomatous inflammation, such as mycobacterial or fungal IRD. Measurement of a delayed-type hypersensitivity response to tuberculin by a skin test may help to differentiate immune reconstitution-associated sarcoidosis from mycobacterial IRD, because a response is absent in patients with sarcoidosis [62] but is often present in patients with mycobacterial IRD [4].

CONCLUSIONS

Physicians who treat very immunodeficient HIV-infected patients with ART will encounter immune reconstitution disorders, particularly IRD. These conditions will have their greatest impact in resource-poor countries, where patients are often very immunodeficient and infected with an opportunistic pathogen when therapy is commenced. Research efforts should be focused on increasing knowledge about the immunopathogenesis of these conditions, so that diagnostic tests and prevention and treatment strategies can be improved.

Acknowledgments

Financial support. National Health and Medical Research Council of Australia.

Potential conflicts of interest. M.A.F.: no conflicts.

References

- French MA. Disorders of immune reconstitution in patients with HIV infection responding to antiretroviral therapy. *Curr HIV/AIDS Rep* 2007; 4:16–21.
- Shelburne SA 3rd, Hamill RJ, Rodriguez-Barradas MC, et al. Immune reconstitution inflammatory syndrome: emergence of a unique syndrome during highly active antiretroviral therapy. *Medicine (Baltimore)* 2002; 81:213–27.
- French MA, Lenzo N, John M, et al. Immune restoration disease after the treatment of immunodeficient HIV-infected patients with highly active antiretroviral therapy. *HIV Med* 2000; 1:107–15.
- French MA, Price P, Stone SF. Immune restoration disease after antiretroviral therapy. *AIDS* 2004; 18:1615–27.
- Phillips P, Bonner S, Gataric N, et al. Nontuberculous mycobacterial immune reconstitution syndrome in HIV-infected patients: spectrum of disease and long-term follow-up. *Clin Infect Dis* 2005; 41:1483–97.
- Bower M, Nelson M, Young AM, et al. Immune reconstitution inflammatory syndrome associated with Kaposi's sarcoma. *J Clin Oncol* 2005; 23: 5224–8.
- Soriano V, Puoti M, Garcia-Gascó P, et al. Antiretroviral drugs and liver injury. *AIDS* 2008; 22:1–13.
- Miller RF, Isaacson PG, Hall-Craggs M, et al. Cerebral CD8⁺ lymphocytosis in HIV-1 infected patients with immune restoration induced by HAART. *Acta Neuropathol* 2004; 108:17–23.
- Breton G, Duval X, Estellat C, et al. Determinants of immune reconstitution inflammatory syndrome in HIV type 1-infected patients with tuberculosis after initiation of antiretroviral therapy. *Clin Infect Dis* 2004; 39:1709–12.
- Kumarasamy N, Chaguturu S, Mayer KH, et al. Incidence of immune reconstitution syndrome in HIV/tuberculosis-coinfected patients after initiation of generic antiretroviral therapy in India. *J Acquir Immune Defic Syndr* 2004; 37:1574–6.
- Lawn SD, Myer L, Bekker LG, Wood R. Tuberculosis-associated immune reconstitution disease: incidence, risk factors and impact in an antiretroviral treatment service in South Africa. *AIDS* 2007; 21:335–41.
- Burman W, Weis S, Vernon A, et al. Frequency, severity and duration of immune reconstitution events in HIV-related tuberculosis. *Int J Tuberc Lung Dis* 2007; 11:1282–9.
- Shelburne SA 3rd, Darcourt J, White AC Jr, et al. The role of immune reconstitution inflammatory syndrome in AIDS-related *Cryptococcus neoformans* disease in the era of highly active antiretroviral therapy. *Clin Infect Dis* 2005; 40:1049–52.
- Lortholary O, Fontanet A, Mémain N, Martin A, Sitbon K, Dromer F; French Cryptococcosis Study Group. Incidence and risk factors of immune reconstitution inflammatory syndrome complicating HIV-associated cryptococcosis in France. *AIDS* 2005; 19:1043–9.
- Lawn SD, Bekker LG, Myer L, Orrell C, Wood R. Cryptococcal immune reconstitution disease: a major cause of early mortality in a South African antiretroviral programme. *AIDS* 2005; 19:2050–2.
- Kambugu A, Meya DB, Rhein J, et al. Outcomes of cryptococcal meningitis in Uganda before and after the availability of highly active antiretroviral therapy. *Clin Infect Dis* 2008; 46:1694–701.
- Schrier RD, Song MK, Smith IL, et al. Intraocular viral and immune pathogenesis of immune recovery uveitis in patients with healed cytomegalovirus retinitis. *Retina* 2006; 26:165–9.
- Gray F, Bazille C, Adle-Biasette H, Mikol J, Moulignier A, Scaravilli F. Central nervous system immune reconstitution disease in acquired immunodeficiency syndrome patients receiving highly active antiretroviral treatment. *J Neurovirol* 2005; 11(Suppl 3):16–22.
- Mutimer HP, Akatsuka Y, Manley T, et al. Association between immune recovery uveitis and a diverse intraocular cytomegalovirus-specific cytotoxic T cell response. *J Infect Dis* 2002; 186:701–5.
- Breton G, Adle-Biasette H, Therby A, et al. Immune reconstitution inflammatory syndrome in HIV-infected patients with disseminated histoplasmosis. *AIDS* 2006; 20:119–21.
- Blanche P, Gombert B, Rivoal O, Abad S, Salmon D, Brezin A. Uveitis due to *Leishmania major* as part of HAART-induced immune restitution syndrome in a patient with AIDS. *Clin Infect Dis* 2002; 34:1279–80.
- Batista MD, Porro AM, Maeda SM, et al. Leprosy reversal reaction as immune reconstitution inflammatory syndrome in patients with AIDS. *Clin Infect Dis* 2008; 46:e56–60.
- Couppié P, Abel S, Voinchet H, et al. Immune reconstitution inflammatory syndrome associated with HIV and leprosy. *Arch Dermatol* 2004; 140:997–1000.
- Bourgarit A, Carcelain G, Martinez V, et al. Explosion of tuberculin-specific Th1-responses induces immune restoration syndrome in tuberculosis and HIV co-infected patients. *AIDS* 2006; 20:F1–7.
- Elliott JH, Khol V, Sarun S, et al. Investigation of the pathogenesis and diagnosis of tuberculosis-associated immune reconstitution inflammatory syndrome and antiretroviral therapy-associated tuberculosis using skin testing and a whole blood interferon- γ release assay [abstract WEPE0201]. In: Program and abstracts of the XVII International AIDS Conference (Mexico City). 2008.
- Tan DB, Yong YK, Tan HY, et al. Immunological profiles of immune restoration disease presenting as mycobacterial lymphadenitis and cryptococcal meningitis. *HIV Med* 2008; 9:307–16.

27. Puthanakit T, Oberdorfer P, Punjaisee S, Wannarit P, Sirisanthana T, Sirisanthana V. Immune reconstitution syndrome due to bacillus Calmette-Guérin after initiation of antiretroviral therapy in children with HIV infection. *Clin Infect Dis* **2005**; 41:1049–52.
28. Meintjes G, Lawn SD, Scano F, et al. Tuberculosis immune reconstitution inflammatory syndrome (TB-IRIS): case definitions for adults in resource-limited settings. *Lancet Infect Dis* **2008**; 8:516–23.
29. Scriba TJ, Kalsdorf B, Abrahams DA, et al. Distinct, specific IL-17- and IL-22-producing CD4⁺ T cell subsets contribute to the human antimycobacterial immune response. *J Immunol* **2008**; 180:1962–70.
30. Matsuzaki G, Umemura M. Interleukin-17 as an effector molecule of innate and acquired immunity against infections. *Microbiol Immunol* **2007**; 51:1139–47.
31. Tamburini J, Grimaldi D, Chiche JD, Bricaire F, Bossi P. Cytokine pattern in Kaposi's sarcoma associated with immune restoration disease in HIV and tuberculosis co-infected patients. *AIDS* **2007**; 21:1980–3.
32. Crane M, Oliver B, Matthews G, et al. Immunopathogenesis of hepatic flares in HIV–hepatitis B virus (HBV) coinfecting individuals following initiation of HBV-active antiretroviral therapy. *J Infect Dis* (in press).
33. Lim A, Tan D, Price P, et al. Proportions of circulating T cells with a regulatory cell phenotype increase with HIV-associated immune activation and remain high on antiretroviral therapy. *AIDS* **2007**; 21:1525–34.
34. Manabe YC, Campbell JD, Sydnor E, Moore RD. Immune reconstitution inflammatory syndrome: risk factors and treatment implications. *J Acquir Immune Defic Syndr* **2007**; 46:456–62.
35. Miralles P, Berenguer J, Lacruz C, et al. Inflammatory reactions in progressive multifocal leukoencephalopathy after highly active antiretroviral therapy. *AIDS* **2001**; 15:1900–2.
36. Cinque P, Bossolasco S, Brambilla AM, et al. The effect of highly active antiretroviral therapy–induced immune reconstitution on development and outcome of progressive multifocal leukoencephalopathy: study of 43 cases with review of the literature. *J Neurovirol* **2003**; 9(Suppl 1):73–80.
37. Mollet L, Li TS, Samri A, et al. Dynamics of HIV-specific CD8⁺ T lymphocytes with changes in viral load. The RESTIM and COMET Study Groups. *J Immunol* **2000**; 165:1692–704.
38. Torok ME, Kambugu A, Wright E. Immune reconstitution disease of the central nervous system. *Curr Opin HIV AIDS* **2008**; 3:438–45.
39. Clark BM, Krueger RG, Price P, French MA. Compartmentalization of the immune response in varicella zoster virus immune restoration disease causing transverse myelitis. *AIDS* **2004**; 18:1218–21.
40. Trevenzoli M, Cattelan AM, Rea F, et al. Mediastinitis due to cryptococcal infection: a new clinical entity in the HAART era. *J Infect* **2002**; 45:173–9.
41. Giudici B, Vaz B, Bossolasco S, et al. Highly active antiretroviral therapy and progressive multifocal leukoencephalopathy: effects on cerebrospinal fluid markers of JC virus replication and immune response. *Clin Infect Dis* **2000**; 30:95–9.
42. Lawn SD, French MA. Immune reconstitution disease: recent developments and implications for antiretroviral treatment in resource-limited settings. *Curr Opin HIV AIDS* **2007**; 2:339–45.
43. Colebunders R, John L, Huyst V, Kambugu A, Scano F, Lynen L. Tuberculosis immune reconstitution inflammatory syndrome in countries with limited resources. *Int J Tuberc Lung Dis* **2006**; 10:946–53.
44. Murdoch DM, Venter WD, Feldman C, Van Rie A. Incidence and risk factors for the immune reconstitution inflammatory syndrome in HIV patients in South Africa: a prospective study. *AIDS* **2008**; 22:601–10.
45. Lawn SD, Wilkinson RJ, Lipman MC, Wood R. Immune reconstitution and “unmasking” of tuberculosis during antiretroviral therapy. *Am J Respir Crit Care Med* **2008**; 177:680–5.
46. Braitstein P, Brinkhof MW, Dabis F, et al. Mortality of HIV-1-infected patients in the first year of antiretroviral therapy: comparison between low-income and high-income countries. *Lancet* **2006**; 367:817–24. (erratum: *Lancet* **2006**; 367:1902).
47. Ortega-Larrocea G, Espinosa E, Reyes-Terán G. Lower incidence and severity of cytomegalovirus-associated immune recovery uveitis in HIV-infected patients with delayed highly active antiretroviral therapy. *AIDS* **2005**; 19:735–8.
48. Meintjes G, Lynen L. Prevention and treatment of the immune reconstitution inflammatory syndrome. *Curr Opin HIV AIDS* **2008**; 3:468–76.
49. Crum NF, Ganesan A, Johns ST, Wallace MR. Graves disease: an increasingly recognized immune reconstitution syndrome. *AIDS* **2006**; 20:466–9.
50. Knysz B, Bolanowski M, Klimczak M, Gladysz A, Zwolinska K. Graves' disease as an immune reconstitution syndrome in an HIV-1-positive patient commencing effective antiretroviral therapy: case report and literature review. *Viral Immunol* **2006**; 19:102–7.
51. Vos F, Pieters G, Keuter M, van der Ven A. Graves' disease during immune reconstitution in HIV-infected patients treated with HAART. *Scand J Infect Dis* **2006**; 38:124–6.
52. Kirk AD, Hale DA, Swanson SJ, Mannon RB. Autoimmune thyroid disease after renal transplantation using depletion induction with alemtuzumab. *Am J Transplant* **2006**; 6:1084–5.
53. Loh Y, Oyama Y, Statkute L, et al. Development of a secondary autoimmune disorder after hematopoietic stem cell transplantation for autoimmune diseases: role of conditioning regimen used. *Blood* **2007**; 109:2643–548.
54. Elimelakh M, Dayton V, Park KS, et al. Red cell aplasia and autoimmune hemolytic anemia following immunosuppression with alemtuzumab, mycophenolate, and daclizumab in pancreas transplant recipients. *Haematologica* **2007**; 92:1029–36.
55. Hirst CL, Pace A, Pickersgill TP, et al. Campath 1-H treatment in patients with aggressive relapsing remitting multiple sclerosis. *J Neurol* **2008**; 255:231–8.
56. Kamradt T, Mitchison NA. Tolerance and autoimmunity. *N Engl J Med* **2001**; 344:655–64.
57. French MA, Lewin SR, Dykstra C, Krueger R, Price P, Leedman PJ. Graves' disease during immune reconstitution after highly active antiretroviral therapy for HIV infection: evidence of thymic dysfunction. *AIDS Res Hum Retrovir* **2004**; 20:157–62.
58. Kavvoura FK, Akamizu T, Awata T, et al. Cytotoxic T-lymphocyte associated antigen gene 4 polymorphisms and autoimmune thyroid disease: a meta-analysis. *J Clin Endocrinol Metab* **2007**; 92:3162–70.
59. Saverino D, Brizzolara R, Simone R, et al. Soluble CTLA-4 in autoimmune thyroid diseases: relationship with clinical status and possible role in the immune response dysregulation. *Clin Immunol* **2007**; 123:190–8.
60. Stone SF, Price P, French MA. Dysregulation of CD28 and CTLA-4 expression by CD4 T cells from previously immunodeficient HIV-infected patients with sustained virological responses to highly active antiretroviral therapy. *HIV Med* **2005**; 6:278–83.
61. Haramati LB, Lee G, Singh A, Molina PL, White CS. Newly diagnosed pulmonary sarcoidosis in HIV-infected patients. *Radiology* **2001**; 218:242–6.
62. Foulon G, Wislez M, Naccache JM, et al. Sarcoidosis in HIV-infected patients in the era of highly active antiretroviral therapy. *Clin Infect Dis* **2004**; 38:418–25.
63. Thachil J, Jadhav V, Gautam M, et al. The development of sarcoidosis with the use of alemtuzumab—clues to T-cell immune reconstitution. *Br J Haematol* **2007**; 138:559–60.
64. Bhagat R, Rizzieri DA, Vredenburg JJ, Chao NJ, Folz RJ. Pulmonary sarcoidosis following stem cell transplantation: is it more than a chance occurrence? *Chest* **2004**; 126:642–4.
65. Bilu D, Mamelak AJ, Nguyen RH, et al. Clinical and epidemiologic characterization of photosensitivity in HIV-positive individuals. *Photodermatol Photoimmunol Photomed* **2004**; 20:175–83.
66. Goldberg HJ, Fiedler D, Webb A, Jagirdar J, Hoyumpa AM, Peters J. Sarcoidosis after treatment with interferon- α : a case series and review of the literature. *Respir Med* **2006**; 100:2063–8.
67. Iannuzzi MC, Rybicki BA, Teirstein AS. Sarcoidosis. *N Engl J Med* **2007**; 357:2153–65.